

Foreword to Wilderness Medicine 6th Ed.

by David Shlim MD

Reprinted with Permission

Two hours into my first trans-Pacific flight to Hong Kong (on my way to Nepal), a flight attendant put out a call to see if there was a physician on board. I raised my hand and was taken to see a 22-year-old American soldier who was suffering a moderately severe allergic reaction to peanuts. The young man was flushed, had a diffuse urticarial rash, and felt some swelling in his throat. He was so itchy he could not sit still. The reaction had been going on for 45 minutes. As I looked him over, the captain of the plane came down the aisle to talk to me.

“We're as close as we're going to be to Anchorage,” he said. “We can dump the entire trans-Pacific load of fuel and land there, if you say so.”

I greeted this with disbelief. A few hours into my first trip to Asia, and suddenly I was in charge of the plane. I did not want to land in Anchorage if we did not have to (apart from not wanting to dump 40,000 gallons of fuel into the ocean). I asked the flight attendants to bring me the first-aid kit from the plane. I would give the soldier a shot of epinephrine and an antihistamine tablet, and we could keep going.

“We don't carry a first-aid kit,” came the reply. “We have a few bandages, that's it.”

I looked at the soldier. I did not think he was in danger of dying, but it would be a long flight for him with itchy skin and a swollen face. On the other hand, hundreds of people would be delayed a day or more, at a cost of hundreds of thousands of dollars, if we diverted to Anchorage. It occurred to me that someone on a Boeing 747 with 400 passengers might be carrying a bee sting kit. I asked the flight attendant to make an announcement, and three people raised their hands. I accepted one of the kits, injected the soldier, gave him some diphenhydramine, and watched him quickly improve. I told the captain that we could continue flying to Hong Kong.

Solving problems with what you have at hand is one of the main themes of wilderness medicine, a discipline that had yet to evolve in 1979 when I was on that flight. Ten days later, I was trekking on my way to the Himalayan Rescue Association Aid Post at Pheriche, a yak-herding village at 14,000 feet, near the base of Mt Everest. Eating dinner at a teahouse next to the Thyangboche monastery, I was asked if I could help an 84-year-old Sherpa man just up the valley in Pangboche. He had fallen down his stairs and sustained a scalp laceration the day before. I was not carrying suture supplies, but I had just visited the Kunde Hospital and was familiar with the staff, so I wrote a note to request instruments and suture material. A Sherpa runner carried the note and would return with the supplies the next morning.

In the morning, I walked a couple of hours to Pangboche, where I was led to the house of the man who had fallen down. He lay inside, moaning, and his hair was densely matted with blood. We carried him outside into the sun, where it was warm enough to work and there was good light. I put the instruments in a pot of water and boiled them on the hearth inside. I had no gloves and no sterile field. I poured povidone-iodine into the bowl that held the instruments and used the bowl as my sterile field, reaching into the disinfectant each time I needed to use an instrument. This kept both my hands and the instruments relatively sterile as I worked.

The laceration was truly major. It split the old man's right eyebrow and extended across his forehead and over the crown of his head to the back of his neck. A huge skin flap had been created, so I lifted it up and irrigated underneath it with copious quantities of water I had boiled earlier. I began to sew. The man moaned

and muttered as I worked. I asked one of the Sherpas what he was saying.

“He's saying, ‘Leave me alone. I just want to die.’ ”

I finished the repair and placed a padded dressing on his head. I gave instructions to his son and continued my journey to the Pheriche aid post.

Three days later in Pheriche, the defining case in my wilderness medicine education arrived on the back of a yak. The patient being carried down the valley was a young New Zealand nurse named Barbara. She had not been feeling well for 2 days at 16,000 feet and was no longer able to descend under her own power.

Barbara was alert and oriented, although she appeared very tired. She denied having a headache, nausea, or shortness of breath over the past 2 days, and she had just descended 2000 feet. I gave her a cup of tea. She drank half the cup and then lay down and fell asleep. I sat in a chair across the room and watched her. I half-convinced myself that she looked a little blue, then talked myself out of it. She had just descended a considerable distance, with only mild symptoms of possible altitude illness. She could not have high-altitude cerebral edema (HACE). I continued this internal debate for about an hour, until I felt like I needed to know if she was okay.

I touched her shoulder and spoke her name. She did not respond. I shook her gently, and she shifted slightly and made unintelligible sounds. I shook her more vigorously, but she was unable to wake up. She was no longer just sleeping—she was unconscious.

There was no radio at the aid post. I sent a written note to the park ranger in Namche, requesting a helicopter rescue for early the next morning. I gave her intravenous dexamethasone and put an oxygen mask over her mouth and nose running at 2 liters per minute, trying to conserve the only two small bottles of oxygen that we had on hand. A little while later, she suddenly stirred and vomited all over her sleeping bag. Over the course of the night, she deteriorated steadily. I observed the effects of every additional drop of fluid that leaked into her brain. She became decerebrate, then flaccid, then unresponsive to deep pain. She was clearly dying. It was now just a matter of whether the helicopter would arrive in time. I felt very alone, wondering if there was anything more that I could do.

The night had been completely clear when I had stepped outside before taking a short nap. When I awoke at 6:00 A.M., it was snowing. I did not think a helicopter could fly through the mountains in a snowstorm. I had kept up my hope for rescue all night long, but at that moment I began to feel that she might not make it. When that thought hit me, I found myself emotionally unprepared to watch her die. Alone in a remote aid post, with one Sherpa helper and the patient's best friend, the circumstances were too intimate, the patient too like myself. I realized what it meant to do medicine in a wilderness setting. *You are on your own*. There is no one to call, no one to help. You just have to do the best you can with whatever limited resources you have.

At 10:00 A.M., a Sherpa arrived carrying a portable radio. This enabled me to tell the park ranger how desperate the situation had become. His response was not encouraging. He informed me that he had been unable to reach Kathmandu by radio to request a helicopter. Later in the day, he was finally able to contact Kathmandu, but the trekking company refused to guarantee payment for a helicopter evacuation. The park ranger offered to guarantee the money himself. It got worse from there. A helicopter was ready at the airport, but the pilot had gone home for the day. When they tried to telephone him, they found that the phone lines had just gone dead. By this point, Barbara was completely unresponsive to deep pain and barely

breathing at a rate of 4 times per minute. She had even lost her corneal reflexes.

At least it had stopped snowing.

I sat near the radio, waiting. The park ranger called again.

“Maybe we should just try to organize the helicopter for tomorrow,” he told me.

“She's going to die this afternoon if we don't rescue her,” I replied. “If you can't get a helicopter this afternoon, there won't be any point in sending one tomorrow.”

“Got that,” said the ranger.

Another hour went by. Finally, I heard the ranger's voice.

“Pheriche, Pheriche, Pheriche. This is Namche. The pilot has landed here and set off fuel. He's on his way up the valley, but the weather is bad and he wants the patient ready to go.”

I pulled out the intravenous line, and we secured Barbara in her sleeping bag. Her friend would fly out with her. I stepped outside the clinic and looked down the valley. Clouds whipped past the peaks. I spotted the Alouette III helicopter emerging from the clouds. I had never before been involved in a helicopter rescue, and the miraculous appearance of the aircraft seemed like an angel descending from heaven. The helicopter flew past the clinic, made an abrupt turn, and landed. The pilot shut down the rotors, but left the engine running. He waved impatiently for us to bring the patient. We carried her outside with the help of some trekkers and slid her onto the floor in the back of the helicopter, which immediately took off. We turned our faces away from the dust as the chopper disappeared down the valley, back into the clouds.

It was 3 days before we got word about Barbara. She had arrived in the emergency room at Patan Hospital in Kathmandu an hour and a half after leaving us, having descended 10,000 feet. On arrival at the hospital, she was breathing 18 times per minute and was already responding to pain. Twenty-four hours later, she was sitting up in bed and eating.

Thirty years later, I recognize that the key things I have learned about wilderness medicine were introduced during my experience of caring for Barbara. I was on my own, with no expert to whom I could turn for advice. I had to care for a patient in ways that I had never done in a hospital setting. I had to clean her up, turn her, catheterize her—all by candlelight, in addition to trying to figure out how to medically treat and evacuate her. Although her presentation of HACE remains the most atypical I have ever encountered, I still had to make a diagnosis and act on it, with no further tests or opinions to rely on.

As I reflect back on these events, I still recall the depth of my fear that she would die despite my efforts. I have since witnessed on a number of occasions that this is a not-uncommon feeling among rescuers, who often feel devastated when the person they have tried to rescue ends up dying.

Barbara's illness taught me the value of personal experience. After this episode, the lectures I gave every day that season at the aid post on the prevention of altitude illness carried a sense of personal authority that I could not otherwise have evoked. Symptoms *can* be subtle. Altitude illness really *can* be fatal. Descent really *is* lifesaving.

My career in medicine ran parallel to the development of the field of wilderness medicine. In the mid-1970s, physicians and mountain guides began to meet to discuss what was then called “mountain medicine.” The topics included altitude illness, first aid, frostbite, hypothermia, and evacuation. Lectures and hands-on workshops were included. Gradually the gatherings expanded to include topics of hiking and rafting and the skills that supported those activities, such as water disinfection, treatment of traveler's diarrhea, and heat and cold injury. Because we were no longer talking only about the mountains, this new field was dubbed wilderness medicine. Lecturers shared their anecdotal experiences and opinions, but soon they mined the research literature and carried out investigations of their own. In 1983, the first edition of *Wilderness Medicine* was published. It was also in 1983 that I moved to Kathmandu to begin a 15-year stint working at the CIWEC Clinic Travel Medicine Center and started carrying out my own research into the diseases and injuries that affect travelers in Nepal.

Wilderness Medicine now appears in its sixth edition. Rather than wilderness medicine defining what should be in the textbook, the textbook has helped define what is in the field of wilderness medicine. Instead of focusing solely on traditional areas, the editor has opted for inclusiveness, covering topics that include such stalwarts as lightning and frostbite, but also volcanic eruptions, combat casualty care, alligator and crocodile attacks, global humanitarian medicine, and space travel.

Despite this wide range of knowledge, the specialty of wilderness medicine still has a common denominator: when something bad happens in the field, immediacy and bonding lead to an increased emotional requirement from the rescuers. In addition to diagnosis and treatment of the patient, one is confronted with limited resources and the compounding factors of weather, terrain, and isolation. Not infrequently, rescuers have to place themselves in harm's way. At the very least, they may have to endure their own discomfort and exhaustion. Although these factors create a different dynamic of medical care, ultimately the goal is the same—to ease or prevent suffering in the patient.

The quest for adventure may take travelers to countries with little or no available medical care. Many adventurers think only of *their* personal medical situation or of the risks that *they* are taking in a remote environment. They may give little or no thought to the thousands of people along their routes who can live entire lives without access to even basic medical care. The plight of the world's poorest people may only briefly come to light at those times when a major disaster strikes. Wilderness medicine aficionados have frequently been rescuers in these extreme situations. Their experiences have sometimes taught the physicians what it really means to try to practice medicine on behalf of people who have no resources. They often return with a newly discovered desire to share medical knowledge and skills around the planet on an ongoing basis. They have come to recognize that all human beings are the same in wanting to be happy and free from suffering. Seen in this light, there is no difference between a mountaineer with altitude illness, the traveler with diarrhea, a Tibetan refugee with frostbite, the woman in an African village in the midst of a difficult birth, or a child shivering with the fever of malaria.

My initial attraction to high-altitude medicine had far-reaching consequences in my personal life that I could never have foreseen. After three trekking seasons in the mountains, I moved to Kathmandu, and within a year I had volunteered to be the doctor for a Tibetan Buddhist monastery. The head of the monastery, Chokyi Nyima Rinpoche, became my teacher and close personal friend. By applying his teachings on Buddhist philosophy to my medical practice, I became more the physician I wanted to be—calmer, kinder, clear thinking, and willing to help. Our friendship led to collaboration on a book about how to train in compassion.

I strongly believe that there is a way to connect wilderness medicine to conventional medicine, and even further, to our personal lives. This advice can be condensed into three key principles. First, there is *competence*. We should be advocates of learning and apprenticeship in the backcountry and not be satisfied

with merely attaining just enough fitness to be guided on an adventure. Although one can take pleasure from achieving a distinct goal, one's satisfaction is greatly enhanced by the cultivation of skills gained through lectures, practice in the field, and extensive personal experience.

When one starts to plan a journey or an adventure, one needs to do research and fully understand the limitations imposed by that activity. Are there hazards of weather and terrain that could result in being stranded for long periods? Is there the possibility of rescue? Where is the closest medical care? To what degree are we prepared to accept the situation? *Commitment* means accepting the risks and limitations of a given adventure before facing the challenge, so that one can deal with it realistically. Ideally one would like to avoid having to say, "If I had known it was going to be like this, I would never have gone."

Finally, no matter what happens, one should always make decisions with full consideration of *compassion*. This could involve abandoning one's own goals to help someone else or modifying the trip so that everyone can succeed.

There is a famous Tibetan Buddhist saying that is true in all aspects of our lives, including our wilderness adventures:

All the joy the world contains

Has come through wishing happiness for others.

All the misery the world contains

Has come through wanting pleasure for oneself.

Adventures in the wilderness, by occasionally taking us close to our limits, can teach us a great deal about our true nature. A well-known mountaineer, after living through a major rescue drama on Mt Everest, once said, "The person I wanted to *be* met the person I actually *was*." In such defining moments, I have observed that those who abandoned their own ambitions in order to help others have always ended up happier than those who pursued only their own goals.

The wilderness is a proving ground that draws us in with its physical splendor, then tests us with hardship. We are often changed by these encounters. Whether we perceive these changes as positive or not may depend less on whether we have succeeded in our adventurous goals and more on how we learned to conduct ourselves in pursuit of those goals.

The elderly Sherpa with the head laceration healed without infection and lived for 3 more years, before dying of old age.

David R. Shlim, MD

Author, Medicine and Compassion: A Tibetan Lama's Guidance for Caregivers

Jackson Hole, Wyoming

This article was published in *Wilderness Medicine*, 6th Edition by Paul S. Auerbach. Pages xv - xvii. Copyright Elsevier 2012.

CASE REPORT

They Had Me in Stitches: A Grand Canyon River Guide's Case Report and a Review of Wilderness Wound Management Literature

Susanne J. Spano, MD; Brad Dimock

From UCSF-Fresno Medical Education Program, Fresno, CA (Dr Spano); and Arizona Raft Adventures (AzRA), Flagstaff, AZ (Mr Dimock).

We present a case of failed conservative management of a traumatic wound sustained in a wilderness setting. The patient was initially treated with a povidone-iodine scrub, suture closure, and expectant management by 2 physicians who were paying clients on a multiday river rafting expedition. Empiric antibiotic coverage and irrigation of the dehiscence were initiated several days after initial treatment. The patient arranged his own evacuation 8 days after injury. Hospitalization, intravenous (IV) antibiotics, and surgical debridement with wound vacuum placement led to a full recovery. This case presents several common wound care pitfalls. The sequelae to these pitfalls are more dramatic in a wilderness setting and underscore the importance of early aggressive management and considering prompt evacuation when treating wounds sustained in the wilderness.

Key words: wound management, wilderness medicine, laceration repair, wound infection, prophylactic antibiotics

Introduction

More than 250 million persons visited a national park within the United States in 2012, which meets and exceeds previous attendance records while simultaneously raising the likelihood for potential injuries sustained in wilderness settings.¹ Acute traumatic wounds are common, consistently ranking in the top 10 reasons for emergency room visits for adult males and all pediatric patients under the age of 15.² In wilderness settings, lower extremity musculoskeletal trauma has been reported to constitute up to half of all injuries sustained.³ A comprehensive approach to acute wound care is important in the hospital-based setting, but is especially critical in the wilderness setting, as definitive treatment can be hours to weeks away. The limitation of available medical resources and the variety of acute traumatic wounds present a challenge. Each wound needs individual evaluation to minimize complications of poor wound healing, infection, and long-term functional deficits.

We present a case from the Grand Canyon that illustrates how these factors can come into play with what initially seems like an uncomplicated wound

closure and conservative management strategy. The following narrative comes from Brad Dimock, a veteran Grand Canyon river guide for more than 30 years, whose last season sent him to the operating room twice. Brad Dimock is a legend as a Colorado River boatman, one of very few to have rafted the River at almost 100,000 ft³/s in the infamous Glen Canyon Dam flood of 1983, which was and still is the highest water flow recorded there since early construction work at the Glen Canyon Dam site in 1958.⁴ Record-breaking precipitation in 1983 resulted in Lake Powell reaching its highest recorded level in history and the only time the spillways of Glen Canyon Dam have been opened for floodwater management.⁵ Brad's knowledge of the Colorado River is encyclopedic. He is also a historian and author of several prize-winning books on rafting and the Colorado River, as well as a publisher and President of Fretwater Press. Dimock's style shies away from pedantic relating of facts as he views every subject as another avenue for his greatest talent, storytelling. This case report is his firsthand account.

Case Report

Day 1 (Day 6 of the trip, but Day 1 of the injury). We are at Bright Angel Trail at Pipe Creek with a big exchange.

Corresponding author: Susanne J. Spano, MD, 155 N. Fresno Street, Suite 206, Fresno, CA 93701 (e-mail: sspano@gmail.com).

River trips in the Grand Canyon can take from 2.5 to 5 weeks from Lee's Ferry at river mile 0 to South Cove, Lake Mead, at river mile 297 (Figure 1).⁶ One can shorten their trip by hiking in or out mid-route, which is called an "exchange." The new passengers have all arrived early, and we are hustling to get things rolling and capitalize on the mileage we can make. I hop onto my raft to grab a water jug and slip off the wet, slippery tube. My foot bounces across a couple of loose duffle bags in my bilge, and my shin slams into the frame. "Ow!" says I, thinking, *That really hurt. This might draw blood.* I pull my leg out and am stunned and horrified to see a 4-inch gash to the shinbone, spreading open, gushing blood. I force the gaping wound closed with my hands and hobble to my seat. It's a big wound; I need help (Figure 2).

We have a quick group discussion to decide who should do the cleansing and Steri-Stripping. The bleeding has stopped, but it is yucky looking. Just as we begin, one of our incoming hikers introduces himself as an orthopedic surgeon and offers to help. His friend, an anesthesiologist, offers a full suture kit with lidocaine (Figure 3). They both feel that stitches are really the way to deal with a wound of this magnitude since Steri-Strips are not likely to hold (Figure 4). I defer to their experience and choose to have them handle the situation. They seem competent, intelligent, and optimistic. Six widely spaced sutures are placed after I had shaved my leg (Figure 5). It is then wrapped up with a 3M Tegaderm transparent waterproof dressing, with a 3M Coban self-adherent wrap to protect it. We all think this looks great and prepare to depart. In all,

we don't lose more than a few minutes. There is no dissent on the decision to carry on.

We run the rafts all the way to river mile 104. There we pull the Tegaderm, change to a clean, dry dressing for the night, and celebrate. In the morning, we replenish with a new dry dressing, fresh Tegaderm, and a wrap. This goes on for a couple days and it still looks great. We're all feeling we are doing the right thing.

Night 5. We are 4 days in, and the wound starts looking a little angry and red (Figure 6). The anesthesiologist and orthopedic surgeon start me on trimethoprim/sulfamethoxazole.

Day 6. I rest in the shade while the folks go to Whispering Springs. We still feel like this thing is totally going to be fine.

Day 7. I harbor for the day at Havasu Creek and watch the red area on my shin creep past the Sharpie lines we drew around it the night before. A nurse on the trip takes a look at it and cringes diplomatically when I tell him we're probably going to hit it with bigger antibiotics tonight and see what happens. His doubt is contagious and escalates mine. My ankle is a cankle. The wound is heating up. When a finger is pushed into my shin, the dent stays there. I want to talk it over with the docs, but they are at Upper Beaver Falls. I am not panicking, not yet.

The folks get back too late to do an evacuation the same day, and we blast down to a ledge camp at river mile 162. My medical team (the anesthesiologist and orthopedic surgeon) shares my fears. It's beyond what we want to, or should be, dealing with on the river. It's heading south on

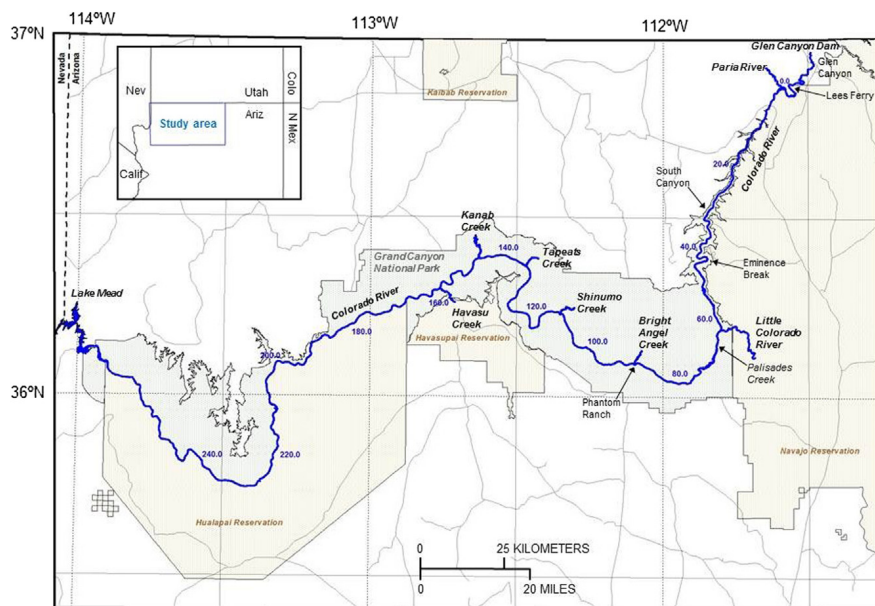


Figure 1. The route of the Colorado River through Grand Canyon National Park.⁶



Figure 2. Initial injury.

us. Since we can't fly at night, they elect to cut stitches, reopen the wound, drain it, wash it, and pack it with povidone-iodine-impregnated gauze. For this surgery, I am instructed to do my own anesthesia—I opt for gin and tonic. GIN and tonic. For douching the wound clean, we use my Flash Gordon squirt gun filled with povidone-iodine solution (Figure 7). It has a far more powerful blast than a syringe. I grimace, laugh, yelp, clench, take pictures, and administer more anesthesia. It's clean now, but I don't even like my steaks to look as cooked as my lower leg does (Figure 8). We begin a second layer of antibiotics, azithromycin, in addition to the trimethoprim/sulfamethoxazole. I feel physically healthy, but the pain and heat in my shin has me terrified. We prepare to launch at first light with the assistants to go find a good southeast window for satellite phone connection and set up the evacuation. All things considered, it's a good plan.

But I toss and turn a lot for much of the night, wretched, scared, and thinking of all the wounds-gone-bad stories I know. The months-in-the-hospital stories. The infection-that-just-won't-stop stories. The loss-of-leg stories. I want to go home really, really bad.

Day 8, 5:35 AM. River mile 163. Contact by satellite phone is made with the National Park Service rangers. A 10:00 AM rendezvous at National helipad is confirmed. I've set up a lot of evacuations in my day, but it's truly weird to be setting up my own. It's a 45-minute helicopter flight to the South Rim of the Grand Canyon with a 1.5-hour drive to Flagstaff from there. At noon I am sitting in a truck with a Big Mac heading for Flagstaff. I enjoy a short-lived optimism.

2 PM. The hospital-based surgeon takes a look, shakes his head, tells me this wound may no longer be closable at this late date, and this may entail a long recovery. The inflammation has reduced a bit, but it looks like hell. I am really, really sad now. It's been a week since I whacked

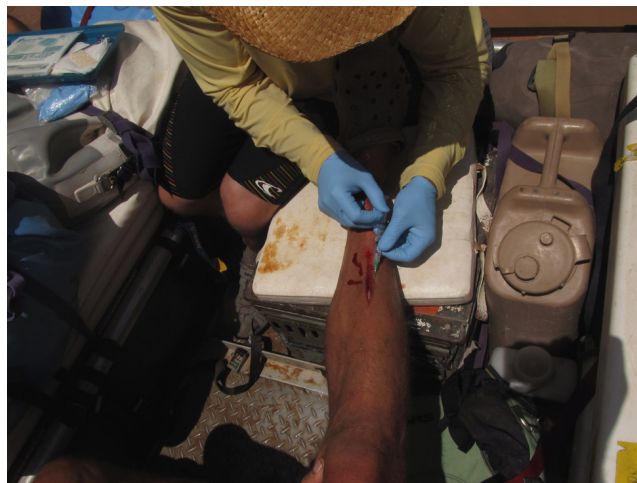


Figure 3. Numbing the wound with lidocaine.

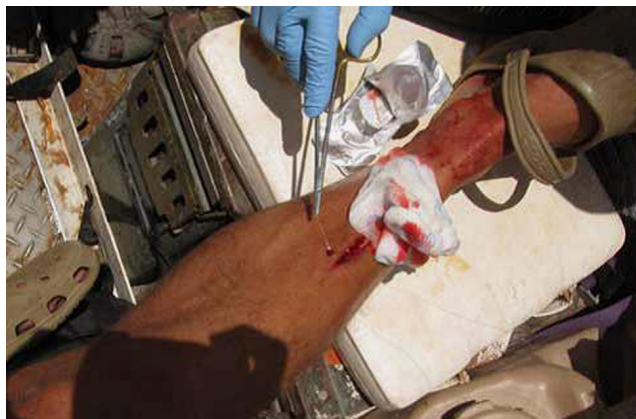

Figure 4. Suturing the wound in the boat.

my shin, and things are majorly screwed up. At 9 PM I am in the operating room (OR). I awake with a wound-vacuum in place, antibiotics, and a wacky thing around my other calf that periodically inflates and squeezes the fluids from my lower leg like an anaconda that occasionally wakes up, flexes around my leg affectionately, and goes back to sleep.

Day 9. I stare at San Francisco Peak out my window. Nice people come to visit me. The wound vacuum keeps gurgling away, the IV keeps dripping, the anaconda keeps snuggling me.

Day 10, noon. Back to the OR. The tissue is healthy (Figure 9). The wound is closed with new stitches, and I am sent home with antibiotics. Days later I see a very happy shin, no redness, no swelling, no heat, and no cankle below (Figure 10). You have no idea how happy I am.

Discussion

In summary, the presented case is of a healthy male without any known risks for suboptimal wound healing

such as smoking, diabetes, or advanced age. His wound was not initially irrigated before closure, but was externally scrubbed with povidone-iodine solution and the leg was shaved. The providers immediately opted for wound closure given the size of the laceration, the personal supplies they had brought, and preexisting expertise with closing wounds in an operative setting. Leaving the wound open was not discussed. The antibiotic choices were made based on the clinical judgment and available resources of the treating providers, and the clinical rationale is not available as the treating field physicians did not coauthor this report. This case brings up the need to have a systematic approach to evaluating injuries and managing the course of wilderness wounds.

Principles of wound management in the wilderness are similar to that of hospital-based management, with the exceptions of evaluating wound appropriateness for closure and often dealing with limited resources for acute wound care.⁷ The objectives of this article are to reinforce a systematic approach to wound assessment, review



Figure 5. Final suture repair on day 1.

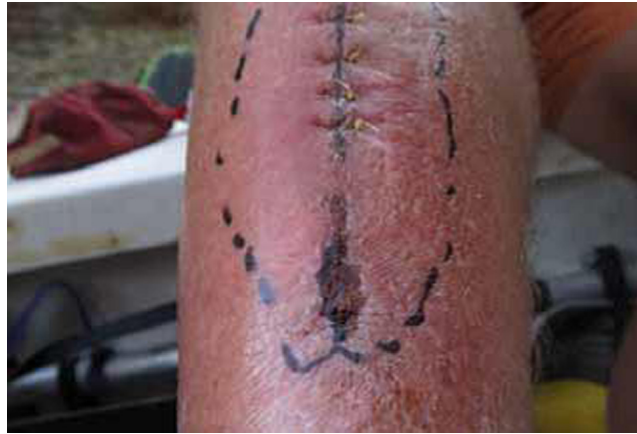

Figure 6. Wound infection on day 5.

evidence-based common pitfalls in provider care, and apply those lessons to the case reported. This review of the current literature will aid the wilderness medicine provider in maintaining a heightened vigilance for what may initially appear to be a minor or uncomplicated injury.

A 2010 wound management review article reviewed common pitfalls in hospital-based emergency management of wounds.⁸ Several errors identified by the authors also impact wilderness wound management. These include failing to provide adequate patient education regarding wound care, use of excessive irrigation (pressure and volume) for clean wounds or for wounds in highly vascularized regions, and irrigation with tissue-toxic solutions such as povidone-iodine, chlorhexidine, or hydrogen peroxide, which can hamper acute wound healing.⁹ As seen in this case, 2 competent physicians translated their common practices in the operating suite erroneously to the wilderness setting. Shaving the skin, high-pressure irrigation, and use of povidone-iodine are practical preoperatively for intact skin, but each can be detrimental to wound health in already injured tissue.

Optimal wound management entails appropriate initial irrigation as well as providing a moist wound environment. Occlusive dressings have lower infection rates than conventional dressings,¹⁰ and moist wound environments accelerate wound healing by up to 50% compared with exposure to air.¹¹ The prehospital providers choose an ideal wound dressing by using a 3M Tegaderm transparent waterproof dressing. This type of wound covering not only keeps a moist environment for optimal wound healing and prevents superinfecting organisms from contaminating the wound, but also allows for visual inspection of the wound without removal because of the transparent nature of the adhesive dressing. However, the treating providers may not have recognized that the wound was contaminated at the moment of insult by the surrounding river water. The only water considered clean, from a wound standpoint, would be water that is potable. This encompasses filtered, boiled, or chemically treated water. Irrigation of wounds with clean water sources can be appropriately managed with manually compressing premanufactured

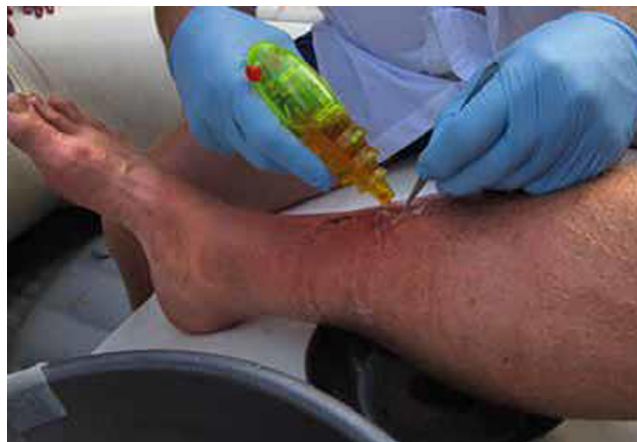

Figure 7. Wound irrigation on day 7.

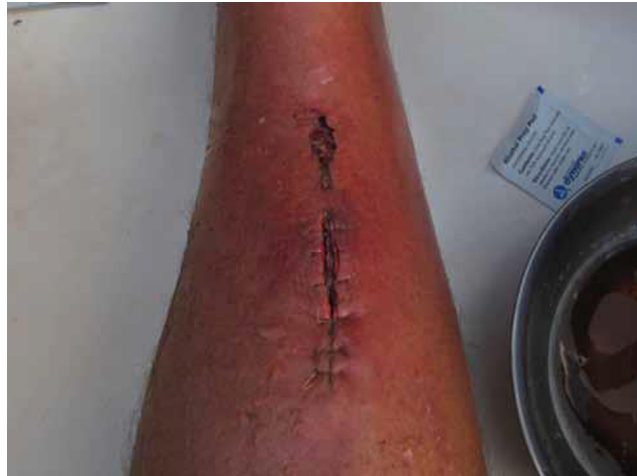

Figure 8. Wound immediately after irrigation.

1-L irrigation bottles, or with a 10- to 20-mL syringe depressed to express clean irrigation solution. Research on the effectiveness of improvised irrigation devices has not yet been published.

Freshwater environments are habitats for several Gram-positive species including the coryneform group and *Bacillus* species.¹² Wounds sustained in this setting require Gram-positive antibiotic coverage.¹³ Freshwater sources are also a host to many Gram-negative species of bacteria, most notably *Aeromonas*, which is relatively resistant to a wide variety of antimicrobials including trimethoprim, cefazolin, and ampicillin.¹² Although rare, *Aeromonas* colonization is more common with penetrating injuries and also should be suspected in rapidly progressing infections.¹⁴ The majority of freshwater-contaminated wounds respond to oral courses of levofloxacin and trimethoprim/sulfamethoxazole.^{14,15} If an *Aeromonas* infection is clinically suggested, one should

arrange for prompt initiation of broad-spectrum IV antibiotics and appropriate surgical care.¹⁵ If this wound had been categorized as a “contaminated wound” on initial examination by the treating providers, the commencement of prophylactic antibiotics on the day of injury would have been reflexive.

Uncomplicated wounds less than 2 cm (just under 1 inch) have been shown to have comparable cosmetic and infection rates whether or not sutured closure is used.¹⁶ Clearly this wound was larger, and loose approximation was arguably a reasonable choice. There is a paucity of literature to support a preferred closure technique for wounds sustained in wilderness settings. Tissue glues, either Federal Drug Administration-approved or commercial cyanoacrylate glues, can be used in a relatively safe and efficacious manner in minor trauma.¹⁷ Adhesive strips have been shown to have similar rates of infection, wound dehiscence, and cosmetic results as sutures, but

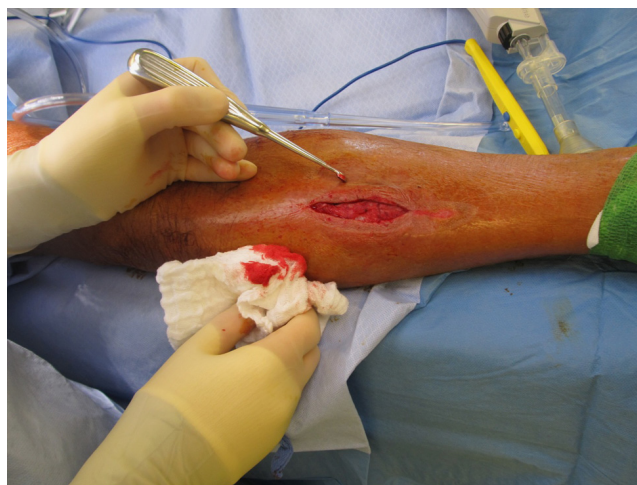

Figure 9. Wound in the operating room on day 10.

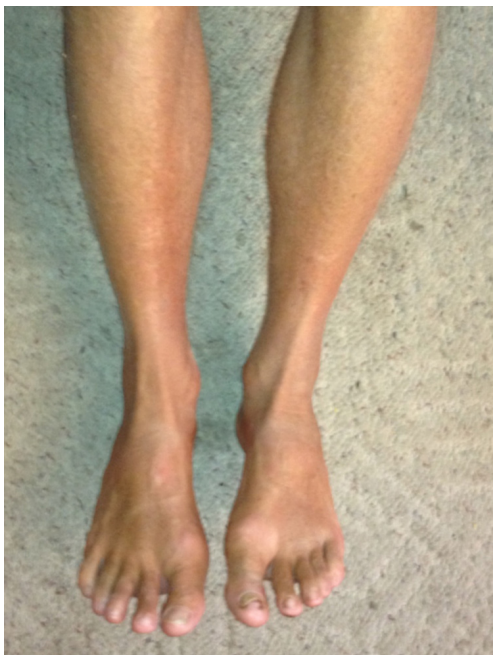

Figure 10. Wound healed (more than 1 year after injury).

have only been systematically compared in small surgical wounds.¹⁸ It is the opinion of the first author that large or high-tension wounds with controlled hemostasis be managed with wet-to-dry dressings and delayed closure. Wounds that require intervention for hemostasis can be sutured, with the provider maintaining a low threshold for evacuation for definitive management. Further study on optimal wound closure in wilderness settings is warranted. The common pitfalls in wound care exemplified by this case stress the point that providers need to dedicate most of their attention to determining whether a wound is truly uncomplicated or not, and then act accordingly given the available resources and the wound environment.

Conclusions

We present a case of a wound sustained in an unclean environment with a delay in empiric antibiotics and evacuation. Providers should consider the potential pitfalls of applying their standard of care routines to wilderness environments, as their knowledge and scope of practice may not translate directly to field practice. Environment-specific microbial considerations as well as limited access to definitive care if wound healing does not proceed as anticipated must be considered in even apparent minor trauma. Wound care principles that were not initially addressed include initial irrigation of the wound and appropriate prophylactic antibiotics at the onset of injury. Further research in wilderness medicine regarding wound appropriateness for closure is warranted.

References

1. Repanshek K. National Park visitation in 2012 rose to nearly 283 million. National Parks Traveler. Online 15 February 2013. Available at: <http://www.nationalparkstraveler.com/2013/02/national-park-visitation-2012-rose-nearly-283-million22827>. Accessed November 22, 2013.
2. The National Ambulatory Medical Care Survey: 2008 Emergency Department summary tables. 2011. Available at: http://www.cdc.gov/nchs/data/ahcd/nhamcs_emergency/2008_ed_web_tables.pdf. Accessed November 22, 2013.
3. Ela GK. Epidemiology of wilderness search and rescue in New Hampshire, 1999–2001. *Wilderness Environ Med.* 2004;15:11–17.
4. National Water Information System, US Geological Survey. Peak streamflow for the nation: USGS09380000 Colorado River at Lee's Ferry, AZ. Available at: http://nwis.waterdata.usgs.gov/nwis/peak?site_no=09380000&agency_cd=USGS&format=html. Accessed November 22, 2013.
5. Wolf TJ. The Bureau showed the Right Stuff: how Lake Powell almost broke free of Glen Canyon Dam this summer. *High Country News.* 1983;15(22):10–14.
6. Davis PA. Natural-color and color-infrared image mosaics of the Colorado River corridor in Arizona derived from the May 2009 airborne image collection. US Geological Survey, Data Series 780. Available at: <http://pubs.usgs.gov/ds/780/>. Accessed September 18, 2013.
7. Joslin J, Auerbach P. Laceration repair in the wilderness. 2008. Available at: <http://www.healthline.com/health-blogs/outdoor-medicine/laceration-repair-wilderness>. Accessed November 22, 2013.
8. Nicks BA, Ayello EA, Woo K, Nitzki-George D, Sibbald RG. Acute wound management: revisiting the approach to assessment, irrigation, and closure considerations. *Int J Emerg Med.* 2010;3:399–407.
9. Rodeheaver GT, Ratliff C. Wound cleansing, wound irrigation, wound disinfection. In: Krasner DL, Rodeheaver GT, Sibbald RG, Woo KY, eds. *Chronic Wound Care.* 4th ed. Malvern, PA: HMP Communications; 2008.
10. Hutchinson JJ, Lawrence JC. Wound infection under occlusive dressings. *J Hosp Infect.* 1991;17:83–94.
11. Fonder MA, Mamelak AJ, Lazarus GS, Chanmugam A. Occlusive wound dressings in emergency medicine and acute care. *Emerg Med Clin North Am.* 2007;25:235–242.
12. Auerbach PS, Yajko DM, Nassos PS, Kizer KW, Morris JA Jr, Hadley WK. Bacteriology of the freshwater environment: implications for clinical therapy. *Ann Emerg Med.* 1987;16:1016–1022.
13. Noonburg GE. Management of extremity trauma and related infections occurring in the aquatic environment. *J Am Acad Orthop Surg.* 2005;13:243–253.
14. Semel JD, Trenholme G. *Aeromonas hydrophilia* water-associated traumatic wound infections: a review. *J Trauma.* 1990;30:324–327.

15. Beckert BW, Puckett CL, Concannon MJ. Analysis of freshwater pathogens: a guide to rational empiric antibiotic coverage. *Mo Med.* 2004;101:219–221.
16. Al-Nammari SS, Quyn AJ. Towards evidence based emergency medicine: best BETs from the Manchester Royal Infirmary. Conservative management or suturing for small, uncomplicated hand wounds. *Emerg Med J.* 2007;24:217–218.
17. Davis KP, Derlet RW. Cyanoacrylate glues for wilderness and remote travel medical care. *Wilderness Environ Med.* 2013;24:67–74.
18. Gkegkes ID, Mavros MN, Alexiou VG, Peppas G, Athanasiou S, Falagas ME. Adhesive strips for the closure of surgical incisional sites: a systematic review and meta-analysis. *Surg Innov.* 2012;19:145–155.

**NATIONAL OUTDOOR LEADERSHIP SCHOOL
INCIDENT REPORT
FALL SEMESTER IN INDIA FRACTURED LEG INCIDENT**

Course: FSI 8/29/2007
Course Leader: Shawn [REDACTED]
Patrol Leader: Punit [REDACTED]
Patrol Leader: Reena [REDACTED]
Student/patient: Dave [REDACTED] age 21; height, 6' 1"; weight, 197 pounds
Incident Date: October 16, 2007
Location: Shalang Valley, Kumaon Himalaya, India
Report by: Drew Leemon, NOLS Risk Management Director; Shawn [REDACTED] Course Leader and Tod Schimelpfenig, WMI of NOLS Curriculum Director.

Table of Contents

Summary of the Incident	1
Pertinent Background Information	2
Sequence of Events	2
Analysis	9
Recommendations	12
Conclusion	12

SUMMARY OF THE INCIDENT

Dave fell down a 30-foot, 35° dirt slope near camp at 12,000 feet elevation in the Himalaya when going to get water for cooking. During the fall he sustained an open fracture of his lower left leg with bone protruding from the wound. Both the Fibula and Tibia were fractured. The instructors and his course mates responded quickly and effectively with first aid and carried him back up the slope to a tent just prior to the start of a significant snowstorm. The NOLS emergency response systems were effectively used and the following morning he was evacuated by helicopter by the Indian military during a fortunate break in the weather and brought to a hospital in New Delhi where he was admitted. Two weeks later he was discharged and was able to return to the U.S. where he was admitted to the New York University Joint Hospital in New York City. He underwent five surgical procedures. His recuperation has gone well and will return to school and has been accepted for an internship at NOLS Pacific Northwest for the summer of 2008.

PERTINENT BACKGROUND INFORMATION

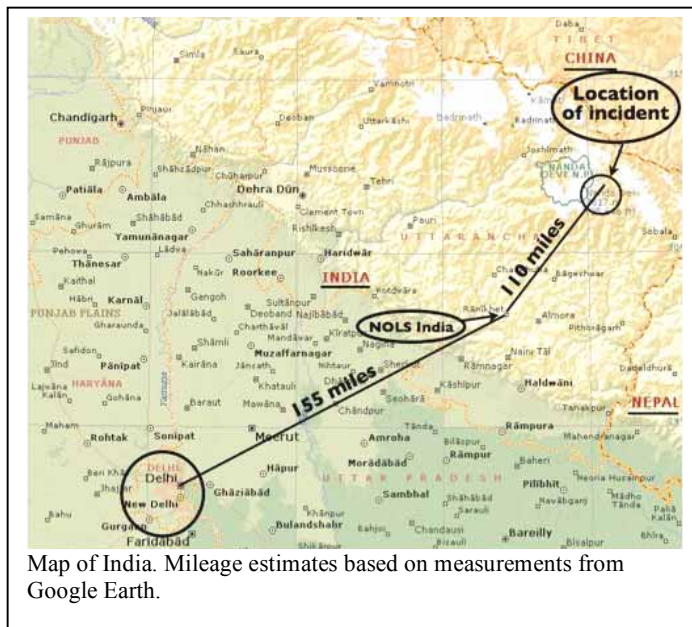
The incident occurred on the 28th day of the semester trekking section (49th day of the semester) in the Himalaya. It had been an unusually challenging course with late Monsoon rains that caused land slides and trail washouts. The landslides closed the main trail for 10 days forcing the group to cross many steep and exposed slopes where normally there would have been a four-foot wide stone path.

The group was camped in the Shalang valley at 12,000 feet, a difficult three-day walk from the nearest road head. Camp was located above tree line on the side of the valley surrounded by 20,000-foot mountains. The ground cover included grass tussocks and three-foot high shrubs.

The weather was cold (30°-35°F) and overcast with light snow flurries throughout the day. The night before it had snowed approximately one foot which then mostly melted to bare ground by midday.

All of the students were graduates of a five-day WMI Wilderness Advanced First Aid course that was part of their semester.

It was a layover day and the students had just returned to camp after a four-hour “solo” experience.



Map of India. Mileage estimates based on measurements from Google Earth.

SEQUENCE OF EVENTS

October 16

3:15 p.m.

Dave went to get water for his tent group from a nearby stream (approximately 300 yards from camp) located at the bottom of a 30-foot hard-packed dirt slope with an approximate average angle of 35°, but close to 45° in places. Dave claims that he was standing on a boulder at the top of the slope that became loose causing him to tumble down the slope stopping near the stream. After the fall Dave realized his lower left leg was broken and on closer inspection saw blood on his lower pant leg and found a wound with bone protruding from it. He claims that a small piece of bone was stuck to his pant leg and he removed it and tried to wash it off in the stream, but then lost it in the water. There were no witnesses.

Dave began to yell to attract the attention of his course mates.

3:30 p.m.

The students heard the yelling and Stacie (a student) went to the instructors' tent to get them.

3:35 p.m.

Several other students heard the yells and located and descended to Dave. The students thought it was a first aid scenario. Jamie (student) was the first student to reach Dave and

he had to lift his left leg so that she could see the obvious deformity caused by the fracture and that it wasn't a scenario.

3:40 p.m.

When Shawn reached Dave he was next to the stream and several students were comforting him while others collected gear that the students above were throwing down to them. Dave said, "Hey Shawn, my bone is sticking out of my leg!"

Shawn quickly assessed the severity of the situation. He had his first aid kit, and anticipating a need to manage Dave's pain, he had Punit retrieve the drug kit.

Dave was in a semi reclined position, sitting on a small rock. He was coherent and reliable and in addition to the leg injury complained of back pain on the lower right side from being struck by a rolling rock. Shawn saw bruising on the lower right side of the back, palpated Dave's spine and did a head to toe exam looking for any other major injuries and bleeding. Shawn found no other injuries and no indication of spine injury, but remained concerned about the possibility of internal injuries.

3:45 p.m.

Dave was administered one Vicodin tablet for pain. Punit went back to camp to call Kutty, NOLS India Director on the satellite phone to request a helicopter evacuation for a limb threatening injury.

3:55 p.m.

Dave, who complained of being cold, was carefully and quickly moved in a seated position to a spot about 10 feet back from the stream and onto a Therm-a-rest sleeping pad. His injured leg was supported with other Therm-a-rests and half ensolite pads. Dave was also wrapped in several sleeping bags and was being reassured by Jamie who was sitting next to his head. The student's first aid training became an asset as two students performed a thorough head-to-toe exam, measured vitals and asked SAMPLE questions (medical history) to complete the assessment, allowing Shawn to focus on the leg injury.

Shawn cut open Dave's rain and fleece pants and saw a 2.5 inch diameter wound exposing the protruding bone on the inside of his lower left leg about 3.5 inches above his ankle. There was also a 0.5 inch puncture wound about seven inches above his ankle and several other minor abrasions.




Photo #1. Incident location. Photo taken after the evacuation as the group was hiking out.

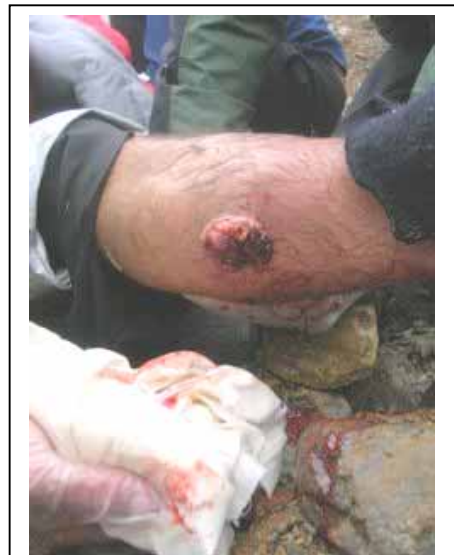

Photo #2. This shows the wound with bone protruding as it looked in the field. His knee is on the left side of the photo, his ankle on the right.

4:10 p.m.

Stacie wrote a SOAP note (record of first aid treatment) and Shawn sent her to Punit so he could provide more information to Kutty on his next phone call.

Kutty initiated the emergency response plan, which includes contacting the U.S. Embassy to inform them of the situation and request their assistance in arranging for a helicopter evacuation with the Indian Air Force who are the only ones authorized and equipped to handle such an evacuation. Dan ██████, NOLS Pacific Northwest Director was also contacted.

Shawn irrigated the wound with water from Dave's dromedary bag (water carrying bag). Disinfected water was not immediately available and he deemed the water at 12,000 feet originating from a nearby ridge to be clean enough. The wound was covered by his pant leg and there were no obvious signs of dirt or rocks on the wound.

Once Dave was semi comfortable and the wounds were cleaned Reena tried to pull traction in line from his ankle in an attempt to provide some pain relief and get the bone to slide under the skin. Reena pulled with considerable force but the bone didn't budge. This maneuver caused Dave extreme pain.

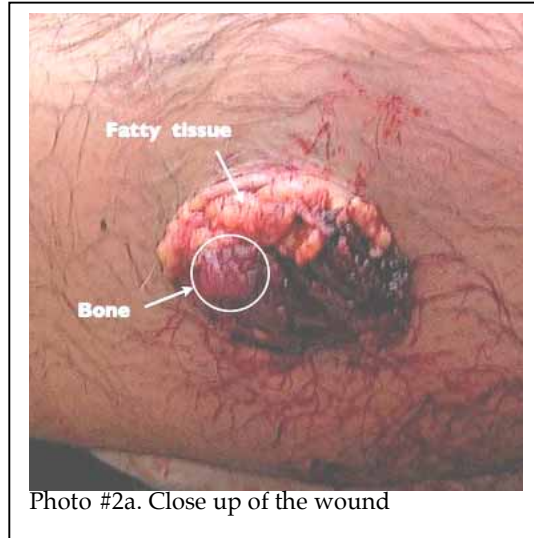


Photo #2a. Close up of the wound

The fracture was treated as an open wound and was dressed with three layers of 3X4" sterile gauze pads with the first pad soaked with water and placed directly over the wound and exposed bone, the second pad dampened lightly and the third pad dry then wrapped with gauze cling. The other small wounds were treated with bandaids.

Prior to wrapping his whole lower leg with a tensor (ACE type) bandage wrap, Shawn noticed a thick 2" "toothpaste-like" cylinder of partially coagulated blood had spurted from his puncture wound where previously no blood had been seen. That wound was bandaged and the leg was wrapped snugly from the top of the calf to the ankle with tensor bandage.

Dave's leg was splinted using his fleece vest and two ensolite half pads. A sock was placed under his slightly bent knee and another sock with the toe cut off was taped around his foot. Two trekking poles, extending from mid thigh to several inches below his foot were tied in place with p-cord padded by strips of ensolite to provide rigidity for the splint. Both legs were then wrapped in a semi inflated Therm-a-rest. An extra jacket and more ensolite was used to pad the area between the legs. The Therm-a-rest was tied with p-cord and then inflated to make an improvised air cast. Dave remained in this splint for the next 24 hours until he reached the hospital emergency room in Delhi.

5:30 p.m.

The group prepared to carry Dave up the slope to where a tent had been pitched. While Shawn was treating Dave, students were scouting for a less steep way up the slope, but the only place was 200 yards away. Shawn and Reena assessed the slope Dave fell down and experimented cutting steps in the hard packed dirt. They decided this was the better way to go even though it was steeper it was less distance (about 60 feet total). Dave was one of the largest students, 6.1 ft, 200 lbs and it would be a struggle to carry him.

It was just about dark and only half of the people had headlamps. The temperature was dropping and Dave was pale and showing signs of shock. The sense of urgency to get him up the slope and into a tent lead to a decision to carry him without a litter. Shawn organized the carry and with Dave lying flat had people line up on either side and stretch their hands underneath him and grasp the hands of the person on the opposite side.

Carrying Dave the first 10 feet was slow but relatively smooth. A quarter of the way up the slope the route steepened to about 45° for about 15 feet. The hard packed dirt provided very little traction and even after cutting steps the dirt turned into a fine dust that further limited their footing. People on the uphill side were completely losing their footing and letting go of Dave as they slid on their backs underneath him. Fortunately there were enough people that as one person would lose grip or become exhausted another person could step in. At this point the situation was very tense as they moved one step at a time before repositioning.

Carrying Dave up the slope was extremely difficult and near the top people became exhausted; holding tight and stepping onto tiny footholds to gain traction. With great determination and effort they got him up and over the lip of the slope. Light snow was now starting to fall. They carried Dave 30 feet further to a tent and once he was settled inside it began to snow heavily and continued for the next 12 hours, accumulating over 2.5 feet.



Photo #3. This photo shows the slope, type of surface, Dave's likely line of fall and the route taken as he was carried up to a tent.

6:30 p.m.

Once in the tent Dave was cared for and made as comfortable as possible. After an hour in the tent and the pain medication took effect the color in Dave's face returned and he became more comfortable, even joking about the situation. He was tended to throughout the night, helping him stay comfortable, monitoring his vitals signs (which remained 'normal' throughout), and maintaining his pain medication (alternating Vicodin with 800 mg ibuprofen in accordance with the NOLS medical protocols).

9:30 p.m.

They learned from Kutty via satellite phone that the Indian Air Force would attempt a rescue mission at first light the next morning, weather permitting. Dave's father had requested to speak with him and they spoke briefly at 10:00 p.m.

Shawn assisted Dave with a bowel movement using an improvised chamber pot. Shawn collected Dave's urine and inspected it for traces of blood. The bruise on his back had been so painful Shawn was concerned there may have been some internal bleeding. There was no blood in the urine.

Throughout the night Shawn and Punit wrote an evacuation report and Dave's course evaluation, kept the snow off Dave's tent, had the students do the same to their tents and were able to get a little sleep.

October 17

6:30 a.m.

The cloud ceiling was very low and snow was still falling. Kutty had been in communication with the helicopter pilot who was on standby at an air force base waiting for the weather to clear before leaving. Dave had a sleepless night but by all accounts was doing well. Throughout the early morning the snow continued to fall but the ceiling was lifting slowly and the barometer was rising rapidly.



Photo #4. Close up view of camp/incident site. Dave fell behind the small ridge where the arrow is pointing.

7:30 a.m.

The previous evening Shawn asked Kutty if he could speak with a doctor or someone with more medical training to get advice on Dave's treatment, long term care of an open fracture and pain management (they only had one Vicodin tablet left when the helicopter arrived). It was arranged for Shawn to call Tod Schimelpfenig, Wilderness Medicine Institute of NOLS Curriculum Director, who was in Lander, Wyoming. Tod reassured Shawn he was doing a good job, that he should look at the wound and Dave's foot for signs of good circulation or signs of dead tissue, and suggested starting Dave on the antibiotic Keflex to fight possible infections.

8:30 a.m.

Shawn administered 500 mg of Keflex to Dave.

9:00 a.m.

The helicopter arrived in Ranikhet to pick up Kutty.

9:30 a.m.

Kutty called Shawn to inform him that the helicopter was departing for the course location. It was due to arrive around 10:30 a.m. though it was still snowing at the course's location. Shawn and the group began to prepare for the helicopter's arrival by moving tents, packing a landing platform in the snow and preparing Dave for the flight. The snow was beneficial because the tussocks were covered and they were able to make an adequate landing zone and better able to mark it with colored koolaid and weighted food zip bags.



Photo #5. Helicopter landing

10:00 a.m.

The snow had eased off and patches of blue sky were visible above the camp.

10:30 a.m.

The helicopter flew up the valley, made three high passes until they spotted the LZ then landed. The pilot powered down but did not turn off the engine keeping the rotor going. The group carried Dave to the helicopter and he was loaded aboard. The windblast during the landing damaged one tent. Kutty dropped off sleeping bags and clothes to replace items used in the splint.



11:00 a.m.

The helicopter with Dave aboard lifted off and departed for New Dehli.

The group was elated and amazed by what had just taken place over the last 20 hours. They hugged and congratulated each other for a job well-done then set about the business of restoring order to their camp and the course. It began to snow again.

They inspected and inventoried gear, repaired the damaged tent, put camp back together, planned a meeting to debrief the incident and began to prepare for independent student group travel that would begin the next day. Shawn called Dan [REDACTED] to inform him that Dave was enroute to New Delhi.



Photo #8. The valley before the snowstorm. Camp was on the left side of the valley.

At 4:00 p.m. the snow stopped and the group met for about 45 minutes for a short debrief. The time and location were not the best given the cold, snow and lateness of the day. Shawn shared some thoughts and thanked everyone for their work. A little over half of the students shared comments, which mostly pertained to how disappointed they were to see Dave leave and amazed with the way instructors handled the situation. (At end of the semester section the students were asked if they wanted to talk about it more and none did. The instructors also checked with each student individually during evaluations. The students seemed to be handling things fine.)

11:45 a.m.

The helicopter landed at an Army base at Dharchula for refueling. Due to miscommunication between the army and the air force this stop last two hours. During this time Dave was doing well. He needed some assistance to relieve himself and was hungry. Kutty advised not eating pending likely surgery that evening.

1:45 p.m.

Helicopter departed army base in Dharchula.

3:30 p.m.

The helicopter landed at the Air Force station of New Delhi Airport where an ambulance from Apollo Hospital was waiting. The U.S. Embassy arranged for permission for the ambulance to enter the restricted area to within 50 feet of the helicopter.

4:30 p.m.

Dave arrived at the Apollo Hospital Emergency Department, approximately 25 hours after the incident.

For the next three hours various teams of doctors examined him. During this time he was probably in more pain than he had been in all day. He had been given the maximum pain medication that could be given before surgery.

7:30 p.m.

Dave was taken in for surgery. The surgeon told Kutty that over the next month that five different surgeries would have to be performed and that Dave would have to be in hospital for this period of time. Kutty passed on this information to Dave's father Rick. Kutty was also able to have Rick speak with Dave before he went into surgery.

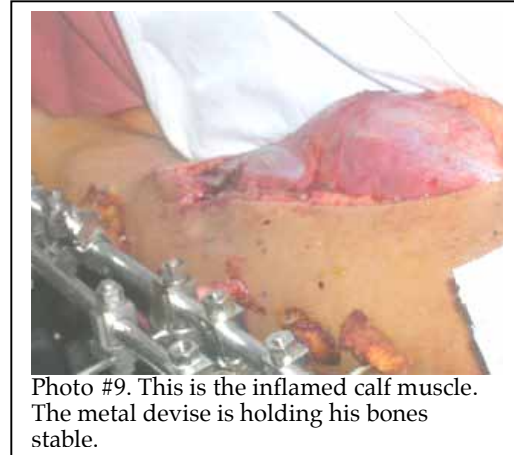

Photo #9. This is the inflamed calf muscle. The metal devise is holding his bones stable.

10:30 p.m.

The surgeon told Kutty that the surgery had gone well. They used a procedure called "external fixation" to keep the bones together. An incision of about 10 inches on Dave's calf was necessary to relieve pressure from the compartment syndrome¹ that developed in his leg. His calf muscle became so inflamed that it threatened the circulatory system in his leg as the muscle swelled to surround the bone to support it.

11:00 p.m.

Kutty spoke with Rick to pass on this information. Kutty mentioned that he would need to return to Ranikhet because another course was to begin soon. Rick was encouraged to come to New Delhi, and take the next steps in getting Dave home. Rick was arranging a visa and flight to India.

October 18:

10:00 a.m.

Kutty met Dave who seemed cheerful and positive. His mother and a friend had spoken with him earlier in the morning. Kutty arranged for Rick to be picked up at the airport and brought to the hospital where they discussed next steps. Rick felt that he would better serve the cause by returning the US after a few days and preparing for Dave's arrival.

October 19:

Kutty returned to Ranikhet. Rick stayed on for a couple more days and returned to the US on Oct 21

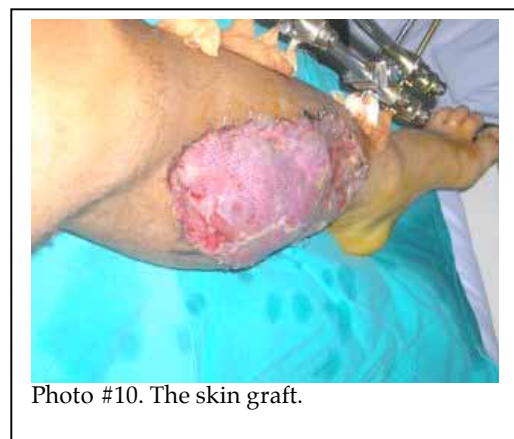

Photo #10. The skin graft.

¹ Compartment syndrome occurs when pressure, usually caused by inflammation, in a confined space in the body impairs blood supply, leading to nerve damage and muscle death if untreated.

October 28

Shawn and Punit visited Dave in the hospital, he was doing well and had undergone multiple surgeries. His treatment had been focused on preventing infection and relieving the compartment syndrome. The surgeon told Dave that if evacuation had been delayed a day or two longer it was likely Dave would have lost part of his leg.

A skin graft was necessary to cover the incision.

Dave was scheduled to fly home to New York the next evening.

October 29

Dave was taken from the hospital to the airport by ambulance. Dave's father, Rick, had arranged through the U.S. Embassy for Dave to be escorted through security and to the gate and for assistance on the flight. The escort did not show up. By chance David and Nancy [REDACTED] who were traveling in India were on the same flight. David is a NOLS graduate and member of the NOLS Advisory Council. David and Nancy offered to help Dave through the airport and during the flight. The airline allowed Dave to board. David and Nancy then accompanied him during the flight and to meet his father upon arrival in Newark.

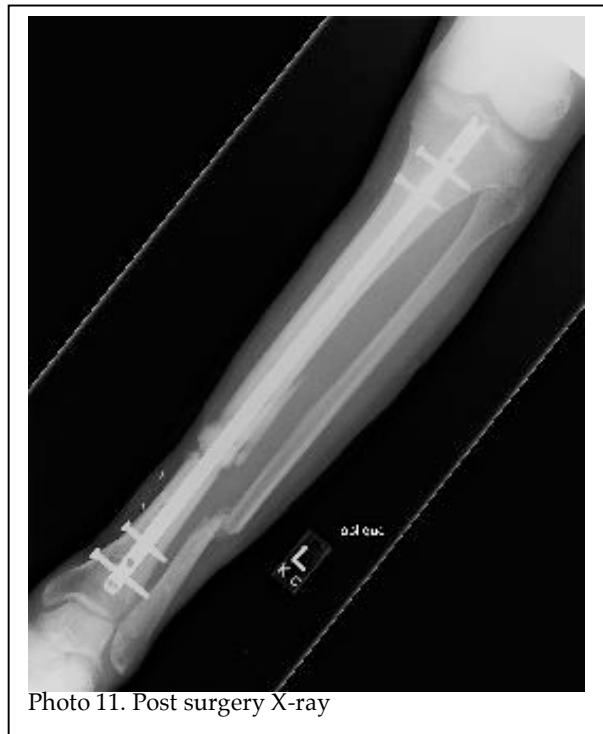November 2

John [REDACTED] NOLS Executive Director and Dan [REDACTED] NOLS Pacific Northwest Director, each spoke to Rick [REDACTED] at separate times. Rick stated that the instructors did an impressive job caring for Dave in the field and that they have continued to stay in contact and this continuing contact has helped Dave feel supported.

November 5

John [REDACTED] visited Dave in the New York University Hospital for Joint Diseases. He was in some pain (and on pain medication) but was very talkative. That day he got on crutches for the first time.

Dave had positive things to say about his course and was generally pleased with the medical care he received in Delhi, although he had a bit of critique. His prognosis for recovery is good, but he will require extensive rehabilitation.



November 30+

We have stayed in touch with Dave and he is recuperation is proceeding well.

ANALYSIS

Fall/slip on Steep Terrain

The steepness of the terrain and the loose unstable surface were the primary contributing factors leading to this incident. Dave's rationale for choosing this more difficult route to the water source instead of the one normally used while the group was camped at this location is unclear. There may have been some sense of urgency to get the water to start the evening meal due the dynamics of Dave's tent group. This may have been a subjective factor that put

him on a more hazardous part of the slope. In addition his shoelaces were untied and he was wearing plastic bags on his feet (inside his shoes, a standard practice to keep socks dry in wet conditions) though we do not know if these were direct contributing causes of his fall.

Supervision

The group was adequately supervised. At the point in the semester when the incident occurred the students had been on a shorter hiking section, were graduates of a Wilderness Advanced First Aid course taught by NOLS, it was the 49th day of the semester, the 28th day of the trekking section, and the third day at this particular camp. The students were experienced in the terrain and it was reasonable and appropriate to permit a student to decide how to get water.

First Aid and Patient Care

The instructors provided excellent care to Dave. We need to remember that while they are well trained as Wilderness First Responders their medical experience is limited and this is the worst field injury they had seen. The wound was cleaned and dressed per the NOLS Medical Protocols and standard wilderness medicine practices and an infection, which is a real risk in this type of injury, did not develop. He was specifically assessed for a spine injury prior to being moved and a decision was made that spine precaution was not needed. The splint was supportive and protected Dave during the difficult carry from the scene to the camp. He received ongoing patient assessment, the staff was aware that shock was not developing as a concern. His pain was managed in accordance with the NOLS Medical Protocols.

Keflex could have been started earlier. The NOLS Medical Protocols state: "Patients with contaminated wounds, open fractures, or deep puncture wounds should take prophylactic systemic antibiotics (e.g. Keflex)." This point was simply over-looked by the instructors. Any mis-perceptions by the instructors of the role of antibiotics in wound care are worth noting and addressing in the next revision of the protocols.

Calling for Medical Advice

It was appropriate that Shawn sought out medical advice and the satellite phone worked well. Tod is an invaluable resource in this regard and in addition we have our physician advisor, Dr. [REDACTED], and an extensive network of other physicians and medical expertise that are familiar with NOLS that we can contact.

Moving Dave Back up the Slope

Carrying Dave backup the hill was quite a feat and though successful raises questions about whether in hindsight a litter should have been constructed and used. Shawn stated that they did not have a rope with them. A small diameter rope is a useful piece of equipment to have for mountain travel. It would have been useful for making a simple and quick litter that might have made carrying Dave up the slope easier and provide more security during the carry by providing hand holds rather than reaching underneath and holding other people's hands.

Evacuation Response

Our emergency procedures worked well. Kutty has kept the documentation up-to-date and he is thorough in briefing instructors on the procedures. The satellite phone worked well and our emergency notification system worked as planned. Kutty contacted Lynn [REDACTED] at the U.S. Embassy to request evacuation assistance from the Indian Military and this request was responded to promptly.

Kutty has done a great job fostering relationships at the U. S. Embassy over the years as staff have come and gone. It is through this relationship that we are able to secure helicopter usage and access to the Apollo Hospital.

Due to the camp's location at almost 12,000 feet and absence of a level landing zone the helicopter was equipped and the crew prepared to extract Dave using a long line and winch. The helicopter did not carry a basket so, if unable to land, Dave would be lifted with only a padded strap placed under his armpits.

It was difficult for the pilot to find and spot the camp location and LZ, which is why he made three passes. It can be very difficult for a pilot to locate a NOLS group and/or landing zone from the air, even if the instructors think the site is well marked. A signal mirror is the best tool for indicating ground position to aircraft. Pilots have told us that bright flashes of light are easily seen while people, colors and smoke are not that obvious.

Being able to pack the snow and cover the vegetation provided a good LZ and allowed for the pilot to land the helicopter thus avoiding the long-line extraction.

The LZ was the same area where the student's tents were pitched. Since it was snowing in the morning Shawn didn't want the LZ prepared until he knew the helicopter was coming. They relied on the satellite phone for this communication.

The tents needed to be located further away LZ and better secured; a tent was blown about by the rotor wash and could have been disastrous if it had hit the rotors.

Shawn was able to inform Kutty and the pilot of the weather conditions at the camp and give them the air temperature. This was important information. If the temperature was above freezing the pilot would not land due to concerns of icing.

Quality of care at Apollo Hospital

The Apollo Hospital is one of a few quality hospitals in New Delhi and part of the largest hospital group in Asia. It also caters to westerners who come to India to get medical treatment at a relatively low cost.

We heard from Dave that his doctors in New York would have set the broken bones sooner using metal rods and treated the wound differently. However, Dave says that the Indian hospital did take very good care of him.

The hospital is comfortable with spacious rooms and Dave was well attended to, though he could not understand much of what the nurses and doctors would say when they came to his room, and he would just go with the flow.

Repatriation to the U.S.

Rick [REDACTED] made the arrangements for Dave's return to the U.S. He was unable to use Dave's return ticket in coach and had to buy a first class ticket. Dave would not have been able to sit in a coach class seat anyway. He was able to purchase the last first class seat on the flight. Rick with assistance from Kutty made arrangements for the ambulance to transport Dave to the airport and for the U.S. Embassy to arrange for an escort for Dave through security to the gate and to inform the airline that Dave would need assistance on the flight. Rick spoke with the Embassy directly about this and was assured things would be taken care of. Kutty was informed by the embassy that the airline (Continental Airlines) was informed of Dave's condition and that their airport manager would be available to assist Dave. This did not happen and if not for the serendipity of meeting David and Nancy [REDACTED] Dave would have been in a difficult situation.

Dave's return to the U.S cost \$20,000 - \$25,000. He was enrolled in the NOLS Tuition Protection Program, which covers medical evacuation and repatriation expenses. Rick was unaware that they had this coverage. We have since informed him and provided the phone number to contact the insurance company.

Rick stated that our staff was terrific. Kutty went out of his way to help and be available and he and Dan [REDACTED] were excellent at keeping Rick informed of the developments during the evacuation and when Dave arrived at the hospital. He also said the instructors did an excellent job of caring for Dave and that the availability and use of the pain medication was invaluable.

RECOMMENDATIONS

1. Consider if a length of rope should be a required equipment item on India backpacking courses.
2. Review and revise the list of physicians and medical experts available to NOLS to provide advise and how they are to be contacted.
3. Review and revise the NOLS Medical Protocols for use of Keflex based on this experience increase the number of Vicodin tablets carried in each drug kit for India expeditions and consider the use of a stronger analgesic for very remote international expeditions.
4. Review and revise NOLS helicopter evacuation protocols emphasizing the need to use a signal mirror to help pilot's locate LZ.
5. Review options for repatriation and what if anything NOLS could do to make this smoother.

CONCLUSION

Slips and falls are a leading cause of injuries in wilderness travel and this incident illustrates how a fall in steep mountainous terrain, no matter how simple it might seem, can, by virtue of where it occurs, result in a serious injury. Mountain travel demands careful attention to a variety of hazards at all times. It's easy to be lulled into a false sense of security after long periods in the mountains, but regardless of one's personal comfort level or confidence an easy task, fetching water for dinner, can become a major life and limb threatening event.

This incident, as unfortunate as it is for Dave, also illustrates the importance and value of:

- Skilled instructors and well educated students with wilderness medicine training who can act as a team to respond to and manage a major medical injury in remote and harsh environment.
- Equipping the expedition with appropriate and ample first aid supplies, prescription medication to treat severe pain and a reliable electronic communication devise.
- Supporting the expedition with wilderness medical protocols, carefully crafted emergency procedures and effective emergency response systems enabling a relatively rapid evacuation.

The response by the instructors and students to Dave's injury and the care they provided to him for 20 hours in challenging adverse weather conditions is nothing short of remarkable. Their effort and ability to respond to this situation is greatly appreciated. Our ability to initiate and execute a complex air evacuation is due to the relationships Kutty has maintained over the years with the U.S. Embassy.

We owe special thanks and recognition to the helicopter crew who's skill and courage enabled Dave to be evacuated in the face of challenging weather conditions.

Everyone at NOLS wishes Dave a successful recovery and we look forward to seeing him at NOLS again.